

Severe Wound Infection and Complications Following Traditional Male Circumcision in Rural Somalia: A Case Report of Malpractice in a Resource-Limited Setting

Abdullahi Hassan Elmi, Abdullahi Abdirahman Omar, Najib Isse Dirie, Ahmed Omar Abdi & Bashiru Garba

To cite this article: Abdullahi Hassan Elmi, Abdullahi Abdirahman Omar, Najib Isse Dirie, Ahmed Omar Abdi & Bashiru Garba (2025) Severe Wound Infection and Complications Following Traditional Male Circumcision in Rural Somalia: A Case Report of Malpractice in a Resource-Limited Setting, International Medical Case Reports Journal, , 553-558, DOI: [10.2147/IMCRJ.S522255](https://doi.org/10.2147/IMCRJ.S522255)

To link to this article: <https://doi.org/10.2147/IMCRJ.S522255>



© 2025 Elmi et al.



Published online: 16 May 2025.



Submit your article to this journal [↗](#)



Article views: 206



View related articles [↗](#)






View Crossmark data [↗](#)



Citing articles: 1 View citing articles [↗](#)

Severe Wound Infection and Complications Following Traditional Male Circumcision in Rural Somalia: A Case Report of Malpractice in a Resource-Limited Setting

Abdullahi Hassan Elmi¹, Abdullahi Abdirahman Omar², Najib Isse Dirie^{3,4}, Ahmed Omar Abdi¹, Bashiru Garba⁴

¹Department of Nursing and Midwifery, Dr. Sumait Hospital, Faculty of Medicine and Health Sciences, SIMAD University, Mogadishu, Somalia; ²Dr. Sumait Hospitals, Faculty of Medicine and Health Sciences, SIMAD University, Mogadishu, Somalia; ³Department of Urology, Dr. Sumait Hospitals, Faculty of Medicine and Health Sciences, SIMAD University, Mogadishu, Somalia; ⁴SIMAD Institute for Global Health, SIMAD University, Mogadishu, Somalia

Correspondence: Abdullahi Hassan Elmi, Email aarrkaa@simad.edu.so

Introduction: Traditional male circumcision (TMC) is a common cultural and religious practice in Somalia. However, procedures performed by untrained practitioners under non sterile conditions can result in severe complications. This case report describes the delayed presentation and successful management of a 6-year-old boy who experienced wound infection and complications following a traditional circumcision.

Case Presentation: A 6-year-old boy from Shaan Town, Middle Shabelle region, Somalia, presented with urinary retention, lower abdominal pain, and penile discharge 15 days after traditional circumcision performed using non-sterile equipment. Initially, he experienced painful urinary dribbling progressing to complete urinary retention, accompanied by local infection characterized by swelling, redness, and foul-smelling discharge. Despite oral antibiotics administered at home, his condition deteriorated, prompting hospital admission near Mogadishu, where intravenous antibiotics and catheterization were initiated. Due to worsening symptoms, the patient was referred to our tertiary facility, where surgical debridement and primary closure of necrotic circumcision tissue were successfully performed. Postoperative recovery was uneventful, with complete normalization of urinary function and resolution of infection. Follow-up examinations at two weeks and one month confirmed satisfactory healing without residual complications.

Conclusion: This case underscores the significant risks of traditional circumcision performed by untrained practitioners, emphasizing the need for public health interventions. This report highlights the importance of integrating safe medical practices into cultural frameworks to improve outcomes in resource-limited settings.

Keywords: wound infection, traditional male circumcision, malpractice, Somalia

Introduction

Traditional male circumcision is a deeply rooted cultural practice in many parts of Africa, with a prevalence ranging from 37% to 90% in some regions such as Kenya, South Africa, Tanzania, and Uganda, but when performed under unsafe conditions, it poses serious health risks and complications.¹

Globally, approximately one-third of males are circumcised, with prevalence varying widely across regions, and, like any surgical procedure, circumcision carries the risk of complications influenced by factors such as surgical technique, provider expertise, and postoperative care.^{2,3} Male circumcision (MC) is a widely practiced procedure affecting approximately 900–1400 million men globally, primarily for prophylactic, religious, cultural, or therapeutic reasons, with the highest prevalence in Africa, the Middle East, Asia, Australia, and the United States.⁴ In Somalia specifically, strong cultural and religious norms promote traditional circumcision as a religious obligation, creating social pressures that often delay families from seeking qualified medical care due to fear of stigma and adherence to tradition.⁵

The most common early complications of circumcision are typically minor and manageable, including pain, bleeding, swelling, and inadequate skin removal; however, severe intraoperative complications, though rare, can be life-threatening, such as excessive hemorrhage leading to death or glans amputation if improperly shielded.⁶ The most frequently observed late complications following circumcision were incomplete removal of the foreskin and the formation of skin bridges adherent to the glans (17.5%), while more severe complications such as partial or complete amputation of the penile glans, tissue necrosis, and excessive removal of penile skin (6.7%).⁷

Medical malpractice in rural Somalia is primarily driven by limited access to quality healthcare, shortage of trained professionals, inadequate medical infrastructure and cultural and religion related norms may delay seeking medical care. Many rural areas lack hospitals and clinics, forcing people to travel long distances for care, which increases their likelihood of receiving substandard treatment. Hence, this case reports the severe complications resulting from traditional male circumcision performed by untrained practitioners in resource-limited settings, illustrated by the case of a 6-year-old boy from rural Somalia.

Case Presentation

A 6-year-old boy from Shaan Town, located 20 kilometers from Jowhar in the Middle Shabelle region of Somalia, presented to our hospital with complaints of urinary retention, lower abdominal pain, and discharge from the head of the penis on day 15 post circumcision. The circumcision was requested by the boy's mother and conducted by a local traditional circumciser, along with three other children, including a younger sibling and two neighbors. The procedure was performed using rudimentary, unsterile equipment. The boy was the first to undergo the traditional male circumcision, and after circumcision, he developed suprapubic discomfort, and initially, the patient experienced incomplete urinary retention characterized by painful dribbling and an inability to urinate. His parents sought advice from the circumciser who dismissed the symptoms as minor and self-limiting. Over the next ten days, despite self-administration of oral amoxicillin at home, the symptoms worsened and progressing to complete urinary retention with total inability to void and he also developed swelling, redness, and foul-smelling discharge from the circumcision site, prompting the parents to seek care at a rural public hospital near Mogadishu.

At the public hospital, the child was noted to have febrile illness and significant distress with evident signs of infection at the circumcision site. The initial management included wound cleaning, intravenous antibiotics, and bladder catheterization to relieve urinary retention. However, due to the severity of the condition, on day 4 post-ward admission, he was referred to our tertiary care hospital for specialized management.

Upon admission to our hospital, clinical evaluation revealed persistent urinary retention and ongoing infection at the circumcision site (Figure 1), and laboratory findings were consistent with elevated inflammatory markers (Table 1). Aggressive medical management, including intravenous fluids, broad-spectrum antibiotics, and regular wound care, was initiated. On the fourth day of hospitalization, surgical repair of the circumcision site was performed under general anesthesia. The procedure involved surgical debridement of necrotic tissue followed by primary closure without graft reconstruction of the circumcision wound. The patient recovered well postoperatively. The child experienced significant clinical improvement, with normalization of urinary function and laboratory findings, and normal inflammatory markers (Table 1).

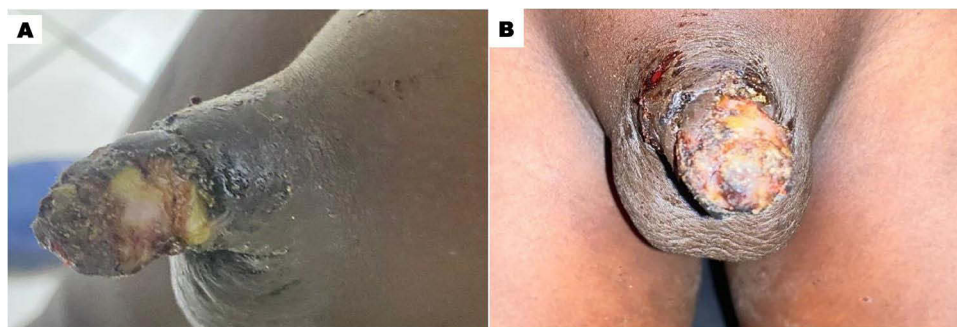


Figure 1 (A) Anterior view of the circumcision site on admission, showing necrosis and severe infection. (B) Lateral view highlighting inflammatory response and wound complications requiring urgent intervention.

Table 1 The Results of Laboratory Investigations

Tests	Reference Range	On Admission	On Ward Discharge
White cell count (WBC, *10 ⁹ /L)	4.00–10.00	32.76	8.34
Hemoglobin (HB, g/dl)	12.0–16.0	10.1	12.3
Platelet (PLT, *10 ⁹ /L)	100–300	666	360
C-reactive protein (CRP, mg/L)	2.5–10	>300	11.3
Aspartate transaminase (AST, U/L)	6–38	28.5	25
Alanine transaminase (ALT, U/L)	6–40	39.0	26.3
Creatinine (Crt, mg/dl)	0.4–1.4	0.35	0.6
Blood urea (Blood urea, mg/dl)	10–50	14.94	32.3
Sodium (Na ⁺ , mmol/l)	135–145	135.9	143.1
Potassium (K ⁺ , mmol/l)	3.5–5.5	4.2	3.6
Calcium (Ca ⁺ , mmol/l)	2.10–2.70	2.2	2.5
Prothrombin time (PT, sec)	10–14	12.69	11.0
Activated partial Thromboplastin time (APTT, sec)	11–45	29.1	35.3
International Normalized Ratio (INR)	0.8–1.1	0.9	1.0
D-Dimer (ng/mL)	50–500	482	335
Blood Group	ABO Rhesus	A+	–
Human Immunodeficiency Virus (HIV)	Positive/Negative	Negative	–
Hepatitis B Virus Antigen (HBVAg)	Positive/Negative	Negative	–
Hepatitis C Virus Antigen (HCVAg)	Positive/Negative	Negative	–

Notes: *Multiplication Sign. + Plus Sign.

The patient was discharged with instructions for wound care and completion of the antibiotic regimen. At the two-week follow-up, the surgical site had healed well, and the child had resumed normal urinary function without complications. At the one-month follow-up, the child remained asymptomatic with no signs of recurrence or residual complications (Figure 2).

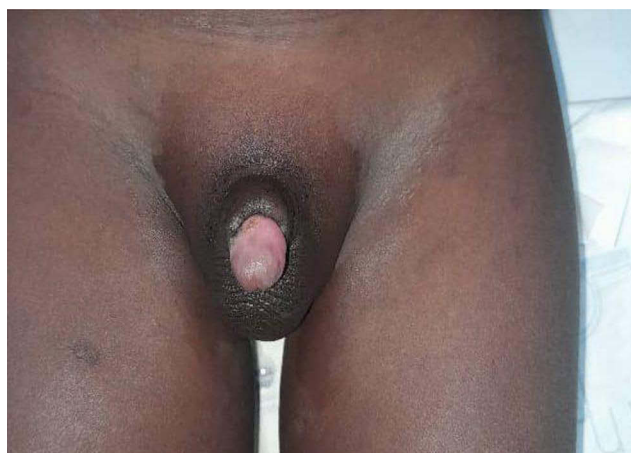


Figure 2 Anterior view of the circumcision site at one-month follow-up, demonstrating complete wound healing.

Discussion

This case highlights severe complications that can result from traditional male circumcision performed under non-sterile conditions by untrained practitioners. Despite initial attempts to manage symptoms at home and in a local hospital, the patient's condition deteriorated, necessitating surgical intervention and wound care at a specialized hospital. Prompt medical and surgical management leads to full recovery, emphasizing the critical importance of early intervention in preventing long-term complications.⁸

Studies from various regions, including South Africa, Nigeria, and Uganda, have consistently reported high rates of complications associated with traditional circumcision include infection, bleeding, urethral injury, and even penile amputation.^{1,2,9} For instance, a study in Nigeria documented urethrocuteaneous fistulae in 10.4% of cases, while another in South Africa highlighted severe sepsis in 56.2% of patients presenting after traditional circumcision.^{1,8,9} Similarly, a study in Yemen described catastrophic outcomes, such as glans amputation and death, further emphasizing the risks associated with unregulated circumcision practices.¹⁰ Amputation of the glans may result from inadequate shielding of the glans during the procedure or the use of inappropriate instruments.⁹ A study by Karl Peltzer et al reported that more than half (53%) traditional circumcisers often rely on nonsterile blades or improvised instruments, which significantly increase the risk of infection and injury likely contributing to the high incidence of complications associated with traditional circumcision.¹¹ This case aligns with these findings but highlights the compounded impact of delayed care in a child, adding to the existing evidence. In Somalia, male circumcision is a widely practiced cultural and religious tradition while the complications of male circumcision are well documented globally, there remains a notable lack of published data from Somalia, where traditional male circumcision is widespread but rarely reported in the scientific literature. A study exploring Somali men's health needs in Sweden noted the widespread practice of circumcision among Somali males, often performed in resource-limited settings by untrained practitioners, leading to complications that are rarely documented or systematically studied.¹² The lack of studies on male circumcision in Somalia contrasts sharply with the extensive focus on female genital mutilation in the region.

Although complications from traditional circumcision are well documented, this case is particularly noteworthy for the delayed presentation of severe complications requiring surgical care. Most reports focus on immediate complications, such as hemorrhage or minor infections.² This case presents a noteworthy clinical scenario in which a pediatric patient developed a severe post-circumcision infection with prolonged urinary retention, yet preserved normal renal function and electrolyte balance. Despite markedly elevated inflammatory markers (WBC $32.76 \times 10^9/L$ and CRP >300 mg/L), indicative of a significant systemic inflammatory response, no biochemical evidence of renal impairment was observed. This outcome may be attributed to the early phase of partial urinary outflow, decreased oral intake during the symptomatic period, and prompt bladder decompression via catheterization upon presentation. These factors likely mitigated the risk of post-renal acute kidney injury by preventing sustained back pressure on the urinary tract. This case underscores the importance of early clinical recognition and timely intervention, particularly in resource-limited settings, where delays in management may otherwise result in irreversible complications despite unremarkable laboratory findings.

This case sheds light on the long-term sequelae of improperly performed circumcisions in rural, resource-limited settings. This underscores the need for public health initiatives targeting the education, regulation, and training of traditional circumcisers to minimize adverse outcomes.

The findings of this case call for urgent public health interventions in regions where traditional circumcisions are prevalent. Training traditional circumcisers using basic sterile techniques and first aid can significantly reduce the complications. Additionally, establishing referral systems and community education programs to promote early medical intervention could improve the outcomes. Integrating medical supervision into cultural practices, as suggested in Uganda and South Africa, may serve as a model for Somalia and similar settings.^{9,13}

This case also raises ethical considerations related to genital autonomy and the rights of children, reinforcing the growing call for culturally sensitive, rights-based approaches to non-therapeutic genital procedures in minors.¹⁴

This case report is limited by its single-patient focus, which may not fully capture the broader spectrum of complications associated with traditional circumcisions. Future studies should aim to quantify the prevalence of these complications and explore culturally sensitive strategies to integrate safe practices into traditional frameworks.

Conclusion

This case highlights the serious risks associated with traditional male circumcision when performed by untrained individuals under nonsterile conditions. Circumcision should not be considered a routine cultural ritual, but rather a medical procedure requiring sterile technique and qualified personnel. Strengthening public health strategies through training, community education, and integration of safe medical practices is essential to prevent avoidable complications and improve surgical outcomes, especially in resource-limited settings.

Abbreviation

TMC, traditional male circumcision.

Ethics and Consent

Written informed consent was obtained from the patient's parent, as the patient was under 18 years of age, for the publication of this case report and the associated images. Ethical approval was not required for case reports at our institution.

Acknowledgments

We sincerely appreciate the Center for Research and Development at SIMAD University for their invaluable guidance and recommendations. Additionally, we extend our heartfelt gratitude to Dr. Najib Isse Dirie for his expert guidance and insightful contributions to this case report.

Author Contributions

All authors contributed substantially to this work, including its conception, study design, execution, data acquisition, analysis, and interpretation. They actively participated in drafting, revising, or critically reviewing the manuscript, provided final approval for publication, agreed on the selected journal, and accepted responsibility for all aspects of the study.

Disclosure

The authors declare no conflicts of interest in this study.

References

1. Wilcken A, Keil T, Dick B. Traditional male circumcision in eastern and Southern Africa: a systematic review of prevalence and complications. *Bull World Health Organ.* 2010;88(12):907–914. doi:10.2471/BLT.09.072975
2. Weiss HA, Larke N, Halperin D, Schenker I. Complications of circumcision in male neonates, infants, and children: a systematic review. *BMC Urol.* 2010;10:2. doi:10.1186/1471-2490-10-2
3. World Health Organization(WHO)/Joint United Nations Programme on HIV/AIDS (UNAIDS). *Male Circumcision: Global Trends and Determinants of Prevalence, Safety and Acceptability.* World Health Organization; 2008.
4. Morris BJ, Wamai RG, Henebeng EB, et al. Estimation of country-specific and global prevalence of male circumcision [published correction appears in *Popul Health Metr.* 2016 Apr 04;14:11. doi: 10.1186/s12963-016-0080-6]. *Popul Health Metr.* 2016;14:4. doi:10.1186/s12963-016-0073-5
5. Wahlberg A, Essén B, Johnsdotter S. From sameness to difference: Swedish Somalis' post-migration perceptions of the circumcision of girls and boys. *Cult Health Sex.* 2018;21(6):619–635. doi:10.1080/13691058.2018.1502472
6. Lerman SE, Liao JC. Neonatal circumcision. *Pediatr Clin North Am.* 2001;48(6):1539–1557. doi:10.1016/S0031-3955(05)70390-4
7. Dörterler ME. Sünnet Komplikasyonları: sekiz yıllık deneyimimiz. *Harran Üniversitesi Tıp Fakültesi Dergisi.* 2020;17:256–260. doi:10.35440/hutfd.762906
8. Ahmed A, Mbibi NH, Dawam D, Kalayi GD. Complications of traditional male circumcision. *Ann Trop Paediatr.* 1999;19(1):113–117. doi:10.1080/02724939992743
9. Anike U, Govender I, Ndimande JV, Tumbo J. Complications of traditional circumcision amongst young Xhosa males seen at St Lucy's Hospital, Tsolo, Eastern Cape, South Africa. *Afr J Prim Health Care Fam Med.* 2013;5(1):488. doi:10.4102/phcfm.v5i1.488
10. Ahmed F, Al-Wageeh S, Ghabisha S, et al. Catastrophic complications of circumcision by traditional circumcisers. *Open Access Emerg Med.* 2021;13:425–429. doi:10.2147/OAEM.S322683
11. Peltzer K, Niang CI, Muula AS, et al. Male circumcision, gender and HIV prevention in sub-Saharan Africa: a social science research agenda. *J Soc Asp HIV/AIDS.* 2007;4(3):658–667. doi:10.1080/17290376.2007.9724889
12. Binder-Finnema P, Mahmud AO, Johnsdotter S, Essén B. "I have made children, so what's the problem?" Retrospective self-circumcision and the sexual and urological health needs of some Somali men in Sweden. *Sex Reprod Healthc.* 2017;11:36–40. doi:10.1016/j.srhc.2016.09.004

13. Report on complications resulting from traditional circumcision in Mbale and Manafwa districts of Uganda. 2012. Available from: https://hivpreventioncoalition.unaids.org/sites/default/files/attachments/3._Study_report_on_trad_circumcising_societies_-_21_Nov_2012.pdf. Accessed January 25, 2025.
14. Brussels Collaboration on Bodily Integrity. Medically unnecessary genital cutting and the rights of the child: moving toward consensus. *Am J Bioeth.* 2019;19(10):17–28. doi:10.1080/15265161.2019.1643945

International Medical Case Reports Journal

Publish your work in this journal

The International Medical Case Reports Journal is an international, peer-reviewed open-access journal publishing original case reports from all medical specialties. Previously unpublished medical posters are also accepted relating to any area of clinical or preclinical science. Submissions should not normally exceed 2,000 words or 4 published pages including figures, diagrams and references. The manuscript management system is completely online and includes a very quick and fair peer-review system, which is all easy to use. Visit <http://www.dovepress.com/testimonials.php> to read real quotes from published authors.

Submit your manuscript here: <https://www.dovepress.com/international-medical-case-reports-journal-journal>

Dovepress

Taylor & Francis Group